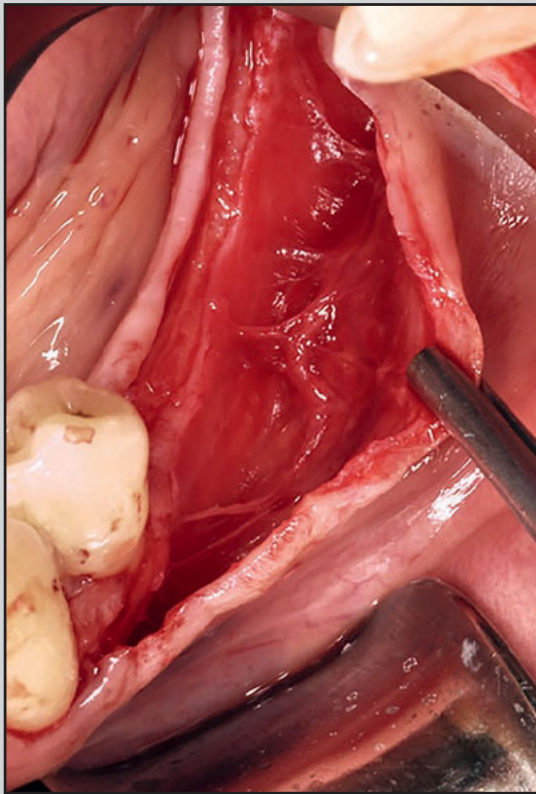
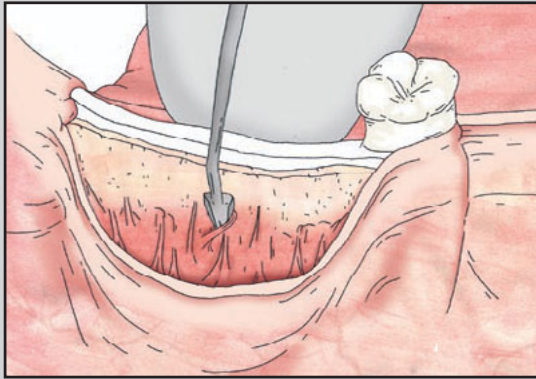
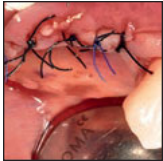Mucosal Detachment Technique for Flap Advancement in a Thin Tissue Phenotype: Technique Illustration



Larissa Steigmann, DMD¹
Marius Steigmann, DMD, PhD²
Hom-Lay Wang, DDS, MSD, PhD³

Passive-tension flap closure of primary wounds remains the most important factor for achieving predictable bone augmentation outcomes. So far, no specific surgical technique has been proposed for major flap advancement, specifically in the thin tissue phenotype (≤ 1.5 mm thick). This article illustrates a detailed description of the Mucosal Detachment Technique (MDT), which separates the mucosal tissue from the underneath periosteum and aims to achieve adequate flap flexibility to cover high-volume augmentation in the thin tissue phenotype. Separating the mucosa from the periosteum allows maintenance of vascularization and an even distribution of tension among the advanced flap. The MDT allows bone augmentation procedures in thin tissue phenotype flap. The flap advancement permits tension-free primary closure in all tissue phenotypes (both thin and thick), independent of the degree of volume augmentation. Int J Periodontics Restorative Dent 2021;41:555–560. doi: 10.11607/prd.5072

Successful membrane coverage is determined by tension-free flap closure and is significant for achieving desirable clinical outcomes.^{1–4} Thus, proper tension release on the overlying flap to achieve passive-tension flap closure remains the most important factor for achieving predictable bone augmentation outcomes.^{1–4} Tension-induced flap openings have been associated with postsurgical complications including infections and graft failure.⁵ Therefore, gaining flap flexibility for the coverage of small- to high-volume augmentation is an important component for predictable outcomes. Several techniques have been described in the literature for flap advancement.^{6–8} Vertical releasing incisions and periosteal scoring are common approaches to obtain flap flexibility.⁹ In addition, it is known that the incision into the submucosa—and sometimes even some deeper, into the muscular layer—could provide major flap advancement.^{6,7,10,11} Nonetheless, the application of these advancement methods are often limited by the amount of overlying tissue thickness. Therefore, determining the periodontal tissue phenotype is relevant to determining the mucogingival surgical management.¹² For a thin tissue phenotype (≤ 1.5 mm thick), it has been advocated to perform a full-thickness flap (periosteum

¹Graduate Periodontics, Department of Periodontics and Oral Medicine, University of Michigan School of Dentistry, Ann Arbor, Michigan, USA.

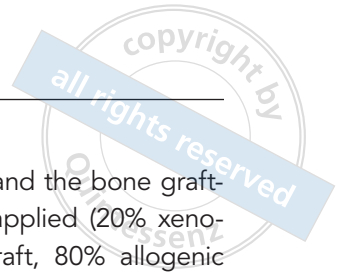
²Private Practice, Neckargemünd, Germany.

³Department of Periodontics and Oral Medicine, University of Michigan School of Dentistry, Ann Arbor, Michigan, USA.

Correspondence to: Dr Hom-Lay Wang, Department of Periodontics and Oral Medicine, University of Michigan School of Dentistry, 1011 North University Avenue, Ann Arbor, MI 48109-1078, USA. Fax: (734) 936-0374. Email: homlay@umich.edu

Submitted April 24, 2020; accepted July 4, 2020.

©2021 by Quintessence Publishing Co Inc.



within the flap) rather than a partial-thickness flap (leaving the periosteum over the bone).¹³ As tissue thickness decreases, wound dehiscence occurs at a higher rate, leading to flap tearing and subsequent graft exposure and case failure.¹⁴ Similar to flap advancement, split-thickness flaps in thin tissue are surgically demanding, as perforation may occur. So far, no specific surgical technique has been proposed for major flap advancement in the thin tissue phenotype.¹⁵ Therefore, the present authors introduce a surgical technique, the Mucosal Detachment Technique (MDT), that separates the mucosal tissue from the periosteum, aiming to achieve adequate dimensions of flap flexibility to achieve primary wound closure.

Technique

The MDT process is illustrated in Fig 1 and shown clinically in Fig 2. Flap access is initiated by a straight crestal incision in the keratinized mucosa, going through the periosteum along the entire incision line (Fig 1a). A complete segregation of the periosteum from the bone must be achieved, otherwise the incision needs to be retraced (Fig 2b). A periosteal elevator is used for flap elevation up to the mucogingival junction. After this, a mucosal detachment approach is performed using a specific instrument (#TKSTEIG2, Hu-Friedy), especially in the thin tissue phenotype (Fig 1b). No vertical incisions are needed for the MDT, and the goal is to leave only periosteum (just 0.3 mm) on the

bone, without any connective tissue attached to the periosteum. Leaving only 0.3 mm of the periosteum attached to the bone helps maintain the entire supraperiosteal blood supply in the overlying mucosa.

The separation of the mucosa tissue from the underneath periosteum is initiated with a periosteal incision in proximity to the bone. Place an instrument with sharp angles but dull cutting (eg, #TKSTEIG2) where the scalpel has created a space (Fig 1b). Now, move the instrument in mesiodistal motions in a continuation of the initial periosteal releasing incision (Figs 1b and 2c). This creates the superficial separation of the mucosa tissue from the periosteum. Use microtweezers to hold the flap and gently pull and stretch it, whilst detaching, in order to visualize the full flap (Figs 2c and 2d). Ensure that mucosa detachment from the periosteum is executed horizontally along the entire flap width. Continue detaching with a semi-dull instrument (eg, #TKSTEIG, Hu-Friedy) to allow for separation of mucosal tissue from the periosteum (Figs 1c and 2c). Lean on the periosteum while peeling off the mucosa tissue with parallel movements. This allows the final separation of the mucosal insertion fibers from the periosteum (Figs 1d and 2d). At this point, the established flexibility of the flap can be adapted according to the primary goal of the surgical procedures, including hard tissue augmentations. In Fig 1, guided bone regeneration (GBR) is performed after full mucosal detachment. After raising the periosteum from the bone (Figs 1e, 1f, and 2d), a periosteal pocket

flap is created, and the bone grafting material is applied (20% xenogenic bone graft, 80% allogenic bone graft; Figs 1g and 2e).¹⁶ A barrier membrane, preferably an absorbable one, may now be placed on top of the bone grafting material that is not covered by the periosteum. The first suture layer is closed by suturing the mucoperiosteal lingual flap to the buccal periosteum using a horizontal mattress technique (Supramid 4-0, Stoma; Figs 1h and 2f). After, a second layer of sutures connects the buccal mucosal flap to the lingual mucoperiosteal lingual flap using modified horizontal mattress sutures (polypropylene 5-0, Hu-Friedy; Figs 1i and 2g). A similar suturing approach has been documented by Buser et al.¹⁷

Discussion

The MDT is a surgical technique designed for flap advancement that can be used for all tissue phenotypes (both thin and thick), especially thin phenotypes. In the thin tissue phenotype, independent of the subsequent augmentation procedure, the mucosal detachment aims to separate the mucosa tissue from the underneath periosteum, with only 0.3 mm of periosteum left. By doing this, the supraperiosteal blood vessels are maintained and flap flexibility is achieved, easily accomplishing primary wound closure. This in turn reduces the procedure's complication rate.

The MDT approach does not require vertical releasing incisions as advocated by many authors for flap

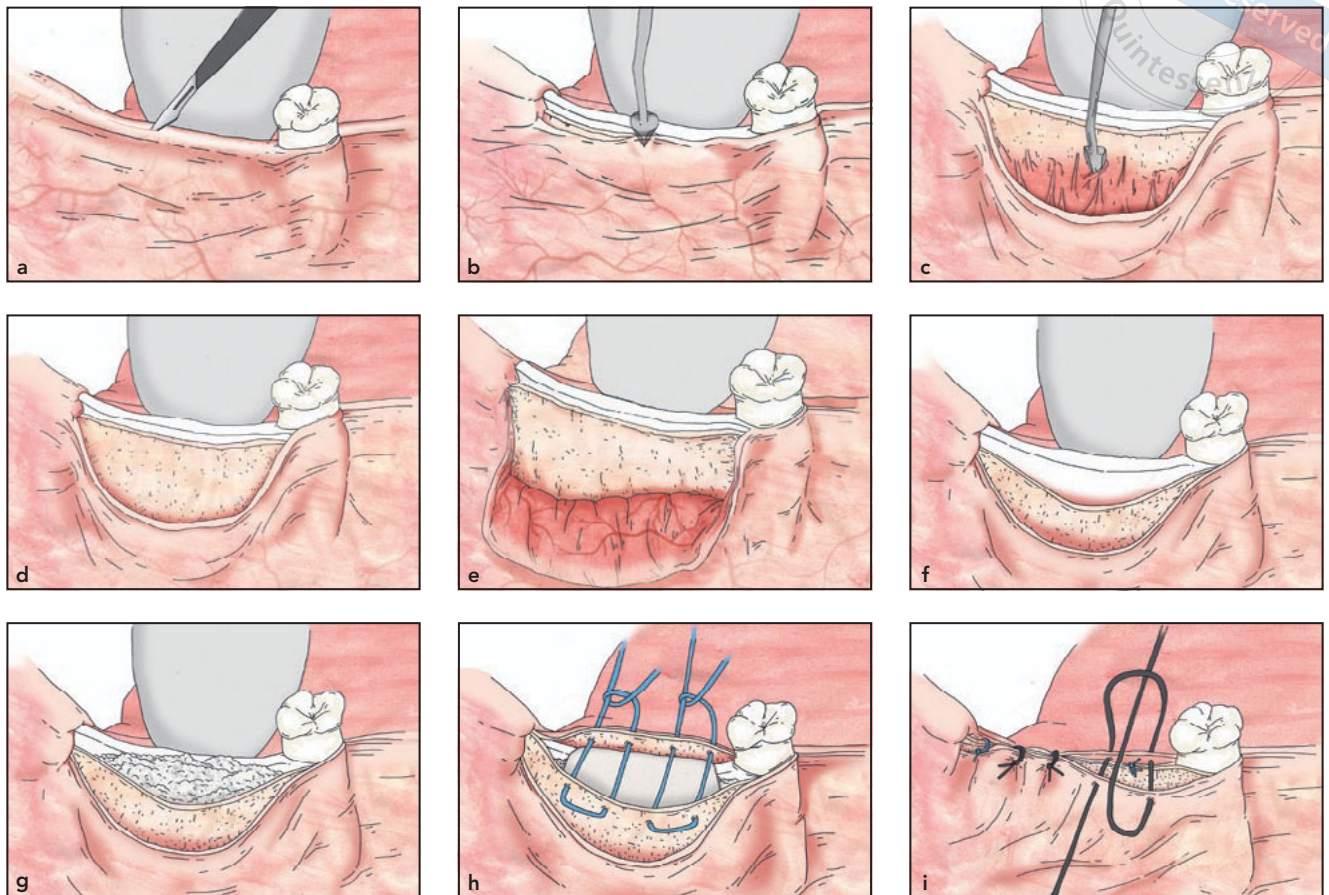


Fig 1 Illustration of the Mucosal Detachment Technique (MDT) sequence for flap advancement in a thin tissue phenotype with a periosteal pocket flap (PPF) and double-suturing technique. (a) A crestal incision in the keratinized mucosa passes through the periosteum. (b) A full-thickness flap is elevated until the mucogingival junction is crossed by 1 to 2 mm; the separation of the mucosa from the periosteum is initiated with a periosteal incision in proximity to the bone. (c) An instrument with sharp angles but dull cutting is placed where the scalpel has created space. (d) The instrument is moved in mesiodistal motions in continuation of the initial periosteal releasing incision to allow for separation of mucosal fibers from the periosteum. The periosteum is still attached to the bone, and suprapariosteal vascularization is maintained. (e to g) In case of GBR, the periosteum is raised from the bone after full mucosal detachment to allow for a PPF and bone graft placement. (h) The first suture layer is closed by suturing the mucoperiosteal lingual flap over to the buccal periosteum using a horizontal mattress technique. (i) The second suture layer uses modified horizontal mattress sutures to secure the buccal mucosal flap to the lingual mucoperiosteal lingual flap.

advancement.⁹⁻¹¹ Although some cases may require vertical releasing incisions (eg, in cases where additional flap advancement is necessary, and a vertical incision can be added in the mucosa), minimizing them and achieving an adequate flap release would certainly be preferred. Park et al investigated the advancement of vertical releasing incisions and periosteal scoring.⁹ The maximal ad-

vancements achieved in relation to the vestibular depth were 24% and 71%, respectively. These findings confirm the limitations of these common surgical procedures. In addition, the MDT creates very minimal tissue trauma, so the postsurgical complications are minimal, which creates a very high patient acceptance rate.

Besides the limitations of flap advancement, the tissue pheno-

type restricts certain mucogingival surgeries to thick tissue phenotype.¹⁴ The probability of preserving thin tissue when performing split-thickness flaps is technically demanding. Burkhardt and Lang demonstrated that the percentages of wound dehiscences for thin flaps (≤ 1 mm) was higher related to the applied forces when compared to thick flaps (> 1 mm). When forces

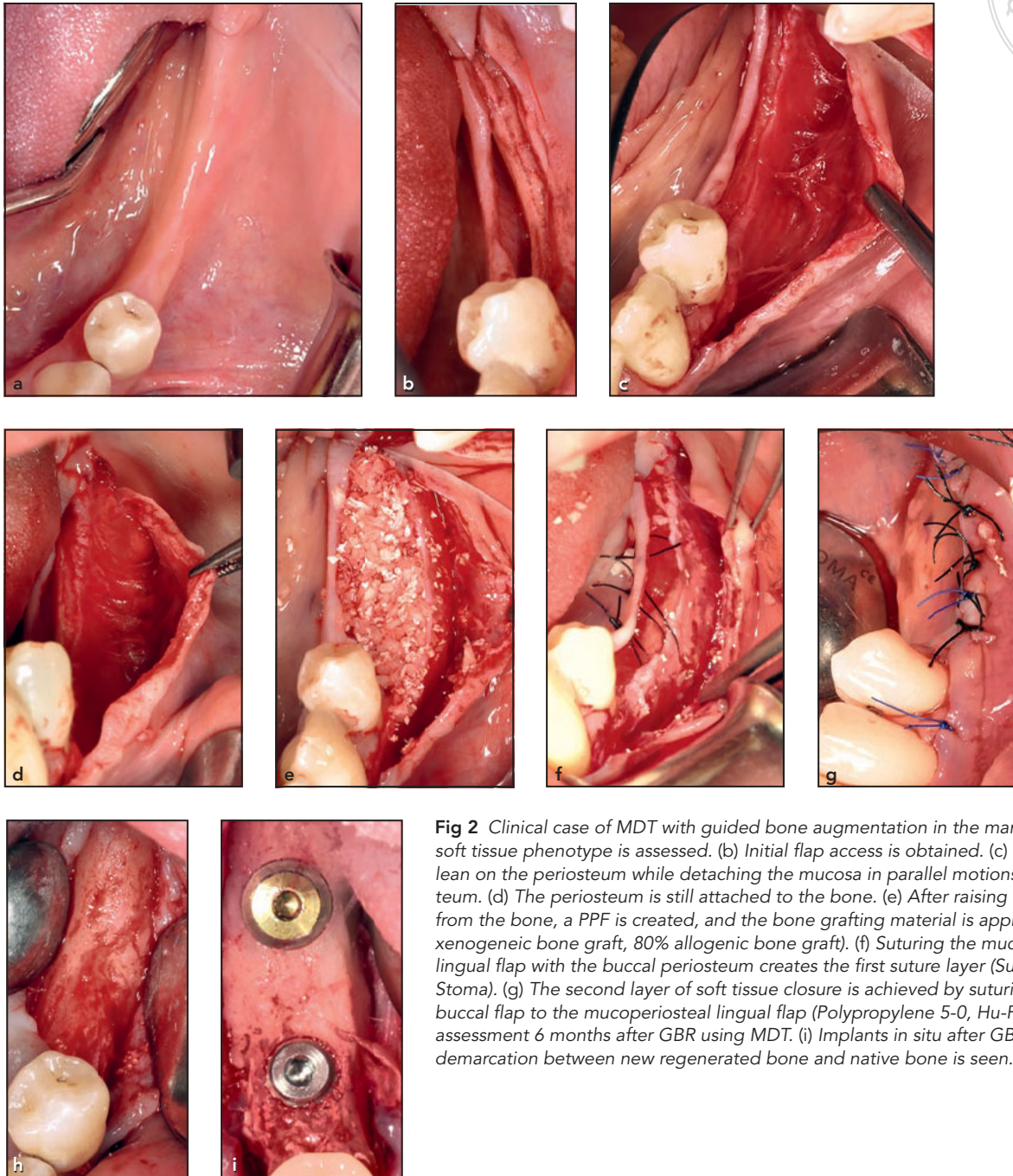


Fig 2 Clinical case of MDT with guided bone augmentation in the mandible. (a) The soft tissue phenotype is assessed. (b) Initial flap access is obtained. (c) One should lean on the periosteum while detaching the mucosa in parallel motions to the periosteum. (d) The periosteum is still attached to the bone. (e) After raising the periosteum from the bone, a PPF is created, and the bone grafting material is applied¹⁶ (20% xenogeneic bone graft, 80% allogenic bone graft). (f) Suturing the mucoperiosteal lingual flap with the buccal periosteum creates the first suture layer (Supramid 4-0, Stoma). (g) The second layer of soft tissue closure is achieved by suturing the mucosal buccal flap to the mucoperiosteal lingual flap (Polypropylene 5-0, Hu-Friedy). (h) Bone assessment 6 months after GBR using MDT. (i) Implants in situ after GBR. No visible demarcation between new regenerated bone and native bone is seen.

> 0.15 N were applied to thin flaps, they reported a wound dehiscence of 100%.¹⁸ The MDT addresses these limitations and overcomes them by detaching the mucosa precisely from the periosteum; rather

than splitting the tissue, the mucosa is peeled off of the periosteum.

While incising the mucosa cuts the blood supply, the mucosal detachment allows the entire vascularization to be maintained within

the flap. Steigmann et al described the splitting of the mucosa from the periosteum without vertical incisions.¹⁶ However, the splitting is arbitrary, and what remains on the bone is periosteum and a random

thickness of connective tissue. Previous studies have reported that compared to periosteal releasing incisions, the mucosal separation decreased patient morbidity by decreasing pain, swelling, and bleeding.¹⁹ The same approach in a thin tissue phenotype would result in a higher complication rate. The clinical scenario in thin tissue phenotype is even more delicate and therefore requires a specific technique and sequence of surgical steps and instruments.

One of the most common complications described with split-thickness flap is hematoma and edema. These complications are the results of injuring the supraperiosteal blood vessels. In 1977, Mörmann and Ciancio investigated gingival blood circulation following various modifications of mucogingival flaps.²⁰ Their fluorescein angiography visualized the major blood supply coming from the supraperiosteal network. The preservation of this vascular network is one of the major advantages when performing MDT.

The difference between split-thickness flaps and the MDT is the total separation of the mucosa from the periosteum. A split-thickness flap leaves tissue on the periosteum, whereas the MDT entirely separates the mucosa apical to the mucogingival junction (Fig 2d). The connective tissue fibers in the periosteum are gradually separated. The detachment creates a broad, spacious flap that allows an even distribution of force, leading to decreased flap tearing.

Disadvantages of the MDT include the technical complexity,

which is determined by the specific sequence of surgical steps that have to be followed meticulously in order to achieve satisfactory clinical outcomes. As the major indication for the MDT is thin phenotype cases, the soft tissue management has to be performed with caution. High-volume bone augmentation in combination with thin tissue phenotype is particularly demanding. A careful selection of instruments combined with surgical experience are required for a successful detachment. Clear presurgical preparation by way of determining the degree of flap advancement and the tissue phenotype are prerequisites for MDT success.

Conclusions

This MDT allows bone augmentation procedures in thin tissue phenotype locations (≤ 1.5 mm thick). The flap advancement permits primary closure for hard tissue augmentations around teeth and implants. Separating the mucosa tissue from the underneath periosteum allows maintenance of the vascularization and an even force distribution among the advanced flap. The MDT will allow tension-free primary closure in all tissue phenotypes, independent of the degree of volume augmentation.

Acknowledgments

Dr Marius Steigmann is the inventor of the mucosal detachment instruments manufactured by Hu-Friedy (#TKSTEIG and #TK-

STEIG2). The remaining authors declare no conflicts of interest.

References

1. Wang HL, Boyapati L. "PASS" principles for predictable bone regeneration. *Implant Dent* 2006;15:8–17.
2. Fu JH, Oh TJ, Benavides E, Rudek I, Wang HL. A randomized clinical trial evaluating the efficacy of the sandwich bone augmentation technique in increasing buccal bone thickness during implant placement surgery: I. Clinical and radiographic parameters. *Clin Oral Implants Res* 2014;25:458–467.
3. Garcia J, Dodge A, Luepke P, Wang HL, Kapila Y, Lin GH. Effect of membrane exposure on guided bone regeneration: A systematic review and meta-analysis. *Clin Oral Implants Res* 2018;29:328–338.
4. Becker W, Dahlin C, Becker BE, et al. The use of e-PTFE barrier membranes for bone promotion around titanium implants placed into extraction sockets: A prospective multicenter study. *Int J Oral Maxillofac Implants* 1994;9:31–40.
5. Fontana F, Maschera E, Rocchietta I, Simion M. Clinical classification of complications in guided bone regeneration procedures by means of a nonresorbable membrane. *Int J Periodontics Restorative Dent* 2011;31:265–273.
6. Greenstein G, Greenstein B, Cavallaro J, Elian N, Tarnow D. Flap advancement: Practical techniques to attain tension-free primary closure. *J Periodontol* 2009;80:4–15.
7. Plonka AB, Sheridan RA, Wang HL. Flap designs for flap advancement during implant therapy. *Implant Dent* 2017;26:145–152.
8. Simion M, Jovanovic SA, Trisi P, Scarano A, Piattelli A. Vertical ridge augmentation around dental implants using a membrane technique and autogenous bone or allografts in humans. *Int J Periodontics Restorative Dent* 1998;18:8–23.
9. Park JC, Kim CS, Choi SH, Cho KS, Chai JK, Jung UW. Flap extension attained by vertical and periosteal-releasing incisions: A prospective cohort study. *Clin Oral Implants Res* 2012;23:993–998.
10. Marzadori M, Stefanini M, Mazzotti C, Ganz S, Sharma P, Zucchelli G. Soft-tissue augmentation procedures in edentulous esthetic areas. *Periodontol* 2000 2018;77:111–122.

11. Urban I, Traxler H, Romero-Bustillos M, et al. Effectiveness of two different lingual flap advancing techniques for vertical bone augmentation in the posterior mandible: A comparative, split-mouth cadaver study. *Int J Periodontics Restorative Dent* 2018;38:35–40.
12. Zweers J, Thomas RZ, Slot DE, Weisgold AS, Van der Weijden FG. Characteristics of periodontal biotype, its dimensions, associations and prevalence: A systematic review. *J Clin Periodontol* 2014;41:958–971.
13. Wood DL, Hoag PM, Donnenfeld OW, Rosenfeld LD. Alveolar crest reduction following full and partial thickness flaps. *J Periodontol* 1972;43:141–144.
14. Baldi C, Pini-Prato G, Pagliaro U, et al. Coronally advanced flap procedure for root coverage. Is flap thickness a relevant predictor to achieve root coverage? A 19-case series. *J Periodontol* 1999;70:1077–1084.
15. Claffey N, Shanley D. Relationship of gingival thickness and bleeding to loss of probing attachment in shallow sites following nonsurgical periodontal therapy. *J Clin Periodontol* 1986;13:654–657.
16. Steigmann M, Salama M, Wang HL. Periosteal pocket flap for horizontal bone regeneration: A case series. *Int J Periodontics Restorative Dent* 2012;32:311–320.
17. Buser D, Dula K, Belser UC, Hirt HP, Berthold H. Localized ridge augmentation using guided bone regeneration. II. Surgical procedure in the mandible. *Int J Periodontics Restorative Dent* 1995;15:10–29.
18. Burkhardt R, Lang NP. Role of flap tension in primary wound closure of mucoperiosteal flaps: A prospective cohort study. *Clin Oral Implants Res* 2010;21:50–54.
19. Ogata Y, Griffin TJ, Ko AC, Hur Y. Comparison of double-flap incision to periosteal releasing incision for flap advancement: A prospective clinical trial. *Int J Oral Maxillofac Implants* 2013;28:597–604.
20. Mörmann W, Ciancio SG. Blood supply of human gingiva following periodontal surgery. A fluorescein angiographic study. *J Periodontol* 1977;48:681–692.